

SONO case series: soft tissue infections, abscesses, pyomyositis and necrotising fasciitis

CASE PRESENTATION

A man aged 65 years with a history of polysubstance abuse, currently on 80 mg daily of methadone in addition to ongoing intravenous drug use (IVDU) presents with 1 week of left arm pain. Patient reports gradual onset of swelling, erythema and pain of the left arm that began shortly after 'muscling' heroin (injecting heroin into the muscle instead of into a vein) into that site. He denies fever, chills, palpitations, chest pain, shortness of breath or other symptoms on review of systems.

Medical history: hepatitis, polysubstance abuse. No surgical history. Home medications: methadone 80 mg daily. No known allergies.

TRIAGE VITAL SIGNS

BP: 146/84 mm Hg, HR: 77 bpm, temperature: 36.8°C, RR: 18 per min, SpO₂: 98%.

PHYSICAL EXAMINATION

Non-toxic male lying in bed comfortably. Exam benign apart from left arm soft tissue exam. Left arm with swelling, erythema and tenderness overlying the lateral bicep. No visible lesion or ulceration. Full range of motion of the shoulder and elbow (figure 1).

LABORATORY DATA

Laboratory data revealed a leucocytosis of 14.6 and elevated lactate of 2.3. The rest of the laboratory values were within normal limits.

Figure 2 shows the point-of-care ultrasound (POCUS) in the diagnosis of left upper extremity.

QUESTIONS

1. What are the indications for performing a POCUS of the soft tissue?
If there is clinical concern based on warmth, erythema, pain, induration or fluctuance, POCUS can aid in the diagnosis of cellulitis and abscess.
2. What clinical questions can be answered when assessing the soft tissue with POCUS?
Are there sonographic findings pointing to cellulitis, abscess, pyomyositis or necrotising fasciitis.
3. Which probe is most ideal in the assessment of soft tissue? What other probes can be used?
The high frequency, linear array probe is best for superficial cellulitis and abscesses. If there is concern for a deeper abscess (like in the gluteus or deltoid), the curvilinear probe may be used for deeper penetration (>5–6 cm).
4. What views are needed to be sure that the soft tissue is adequately evaluated on POCUS?
You must evaluate the full area of erythema and induration, including outside the circumferential border. This must be done in two orthogonal planes for complete assessment. The probe used must also have adequate penetration to evaluate the entire depth of the area involved. When characterising

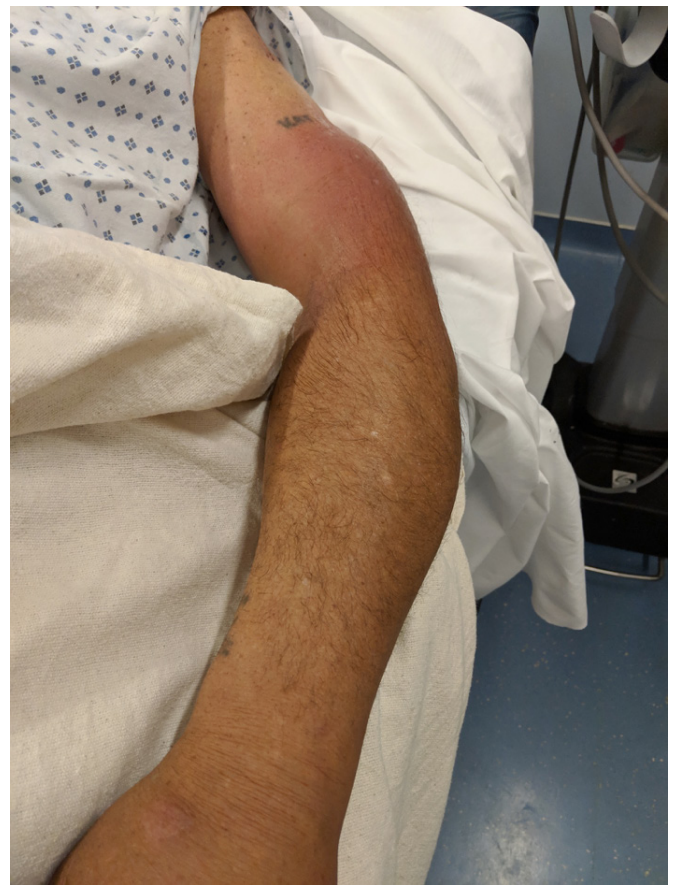

Figure 1 Left upper extremity examination findings.

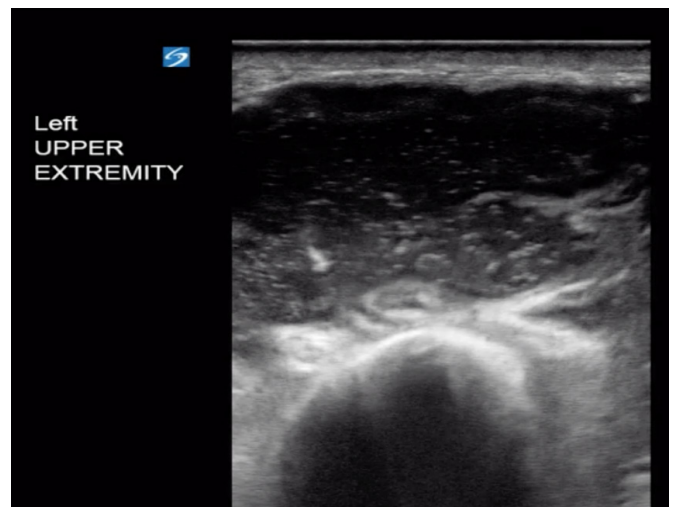


Figure 2 Left upper extremity short axis plane.

the depth of the abscess, the area involved should also be evaluated for foreign bodies and loculations prior to proceeding with an incision and drainage.¹²

5. What are the sonographic abnormalities seen in the soft tissue ultrasound of the left arm?
The ultrasound demonstrates a large collection of fluid, approximately 3×3 cm. The images collected have concerning findings consistent with superficial cellulitis and underlying abscess. The fluid inside of the collection is hypoechoic relative to the surrounding tissue with a sandy echo-texture

typical for pus. It is also notable that the collection is well circumscribed and walled off. The final notable aspect of the ultrasound is the depth of the fluid collection, which extends deep into the fascial layer, into the muscle and appears to neighbour the humerus (figure 3).

6. **What is the differential diagnosis and how can you make the diagnosis with bedside ultrasound?**

Based on the image provided, the differential diagnosis includes cellulitis, abscess, pyomyositis and necrotising fasciitis. On ultrasound, simple cellulitis is represented by ‘cobblestoning’ or oedema of the superficial, subcutaneous tissue alone. An abscess, meanwhile, appears as a well-circumscribed, walled-off collection of hypoechoic or anechoic fluid.

What is most concerning about this image, however, is the depth of the fluid collection. In this patient, the fluid extends below the fascial layer and into the muscle, it also appears to neighbour the humerus. The extension into the muscle and neighbouring bone is highly suspicious for pyomyositis. The reason this is important is when an abscess extends deep into the fascia, the drainage is outside the scope of an ED physician and requires surgical consultation due to the potential for spread and complicated procedure.

Finally, if there is concern for necrotising fasciitis, evaluate along the fascia for signs of gas or fluid. Depending on the type of necrotising fasciitis, the bacteria may be gas-forming or not. Necrotising fasciitis is characterised by fluid or gas tracking along the fascial planes, whereas pyomyositis is a focal fluid collection that is characterised by extension beyond the subcutaneous layer. Necrotising fasciitis is also characterised by its rapid progression and mandatory extensive surgical debridement for source control. Pyomyositis is not usually rapidly progressive and its treatment is simple incision and drainage.

7. **What are some tips when evaluating soft tissue with POCUS?**

The sonographic equivalent of fluctuance is ‘pus-stalsis’, which is created by palpating with the probe with alternating pressure to evaluate for swirling of pus inside the collection. Given the pus can appear hypoechoic or hyperechoic, creating ‘pus-stalsis’ is helpful for identifying the abscess from the surrounding hyperechoic structures. Remember to always evaluate the depth of the infection and evaluate for signs of deeper gas along planes of fascia. The appropriate depth varies based on the area of body, but we recommend always being able to visualise the adjacent layers of fascia and muscle. Finally, when performing the ultrasound of the area

neighbouring the abscess, evaluate for foreign bodies and vascular structures.³⁻⁵

8. **What are some pitfalls of performing POCUS of soft tissue?** Small, circular structures like fingers and toes are difficult to fully image because it is hard to maintain appropriate contact for an ultrasound. This can be addressed by using a step-off (small bag of saline or glove filled with water), water bath or copious amounts of gel. Another common mistake is failing to notice that the abscess is deeper than the fascia or that there is evidence of gas along the fascia concerning for a deep space infection that should not be drained by ED providers. If you see evidence of gas along the fascia, get an X-ray or CT and consider surgical consultation. It is important to remember that necrotising fasciitis can have gas (type III from *Clostridium*) or no gas (type II from methicillin-resistant *Staphylococcus aureus* or group A streptococci). The diagnosis of necrotising fasciitis is confirmed in the operating room (OR) when the surgeon visualises and feels fluid tracking on the fascial planes.

9. **What is the utility of POCUS when assessing the soft tissue?** Based on a recent meta-analysis, ultrasound had a sensitivity of 96.2% and specificity of 82.9% for skin and soft tissue infections.⁶ Ultrasound can be used to mark the outer edges and depth of an abscess before performing an incision and drainage. It should also be used to identify and avoid neighbouring vascular structures before cutting into an abscess. Remember that a CT scan can help demonstrate collections of fluid, abscesses and signs of necrotising fasciitis, but it involves both contrast and a radiation exposure. It is also notable that while an ultrasound, X-ray or CT can help with identifying necrotising fasciitis, ultimately it is clinical diagnosis that requires surgical evaluation regardless of imaging.

CONCLUSION

CT left upper extremity: 5.1×4.1×8 cm abscess with overlying cellulitis. Abscess extends down to humerus.

Given the depth of the abscess and possible presence of necrotising fasciitis, general surgery was consulted in coordination with obtaining a CT scan of the left upper extremity. Ultimately, the patient had a bedside incision and drainage along with washout performed by surgery and >30 mL of purulent material was drained. They did not find evidence of necrotising fasciitis on drainage, which was consistent with both the bedside ultrasound and CT scan. He was subsequently admitted to the hospital and received intravenous antibiotics.

Joseph Roland Brown,¹ William Shyy²

¹Emergency, UCSF, San Francisco, California, USA

²Emergency Medicine, UCSF, Pacifica, California, USA

Correspondence to Dr Joseph Roland Brown, Emergency, UCSF, San Francisco, CA 94143, USA; josephbrown152@gmail.com

Contributors JRB and WS contributed equally to this paper.

Funding The authors have not declared a specific grant for this research from any funding agency in the public, commercial or not-for-profit sectors.

Competing interests None declared.

Patient consent for publication Obtained.

Provenance and peer review Not commissioned; internally peer reviewed.

© Author(s) (or their employer(s)) 2020. No commercial re-use. See rights and permissions. Published by BMJ.

Emerg Med J 2020;37:722–724. doi:10.1136/emermed-2019-208919

ORCID iDs

Joseph Roland Brown <http://orcid.org/0000-0003-4766-1669>

William Shyy <http://orcid.org/0000-0002-2172-9349>

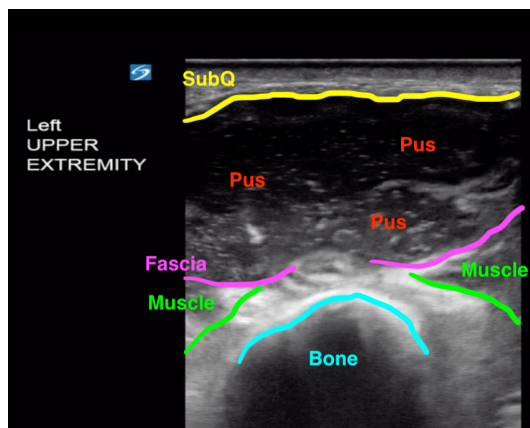


Figure 3 Figure 2 relabelled with tissue layers.

REFERENCES

- 1 Miss J, Frazee B. Chapter 20 – Skin and Soft Tissue. In: Cosby KS, Kendall JL, eds. *Practical guide to emergency ultrasound*. Lippincott Williams & Wilkins, 2013.
- 2 Subramaniam S, Bober J, Chao J, *et al*. Point-Of-Care ultrasound for diagnosis of abscess in skin and soft tissue infections. *Acad Emerg Med* 2016;23:1298–306.
- 3 Berger T, Garrido F, Green J, *et al*. Bedside ultrasound performed by novices for the detection of abscess in ED patients with soft tissue infections. *Am J Emerg Med* 2012;30:1569–73.
- 4 Tayal VS, Hasan N, Norton HJ, *et al*. The effect of soft-tissue ultrasound on the management of cellulitis in the emergency department. *Acad Emerg Med* 2006;13:384–8.
- 5 Nelson M, Reens D, Cohen A. Pyomyositis diagnosed by point-of-care ultrasound in the emergency department. *J Emerg Med* 2018;55:817–20.
- 6 Barbic D, Chenkin J, Cho DD, *et al*. In patients presenting to the emergency department with skin and soft tissue infections what is the diagnostic accuracy of point-of-care ultrasonography for the diagnosis of abscess compared to the current standard of care? A systematic review and meta-analysis. *BMJ Open* 2017;7:e013688.